

---

# Variation of Pulp Canal Configuration in Mandibular Posterior Teeth Using Cone Beam Computed Tomography in Indonesia Subpopulation Mongoloid Race

(Konfigurasi Saluran Akar pada Gigi Posterior Mandibula Melalui  
*Cone Beam Computed Tomography* pada Ras Mongoloid Indonesia)

Trelia Boel<sup>1</sup>, Dewi Kartika<sup>1</sup>, Dennis<sup>2</sup>

<sup>1</sup> Dental Radiology Unit, Faculty of Dentistry, Universitas Sumatera Utara

<sup>2</sup> Department of Conservative Dentistry, Faculty of Dentistry, Universitas Sumatera Utara  
Jl. Alumni No. 2 Kampus USU, Medan  
Corresponding email: trelia.boel@usu.ac.id

---

## Abstract

It is important to understand pulp canal configuration to have a successful endodontic treatment. Cone Beam Computed Tomography (CBCT) radiography is able to assess the pulp canal configuration, especially on the lingual/palatal, compared to the periapical radiography. The objective of the research is to know the prevalence pulp canal configuration of mandibular molar teeth in Indonesia subpopulation Mongoloid race using CBCT radiography. This research is a descriptive survey with a cross-sectional approach, using 38 CBCT radiographs from the patients undergoing dental treatments in hospitals in Medan. The subjects were selected based on research criteria; then their CBCT radiographs were interpreted and analyzed. The result shows the existence of mandibular mesial root type 2-1 (28.94%), 1-2-1 (5.26%), 2-2 (55.26%), 2-1-2-1 (2.64%), 3-2 (5.26%), 3-1 (2.64%), distal root type 1-1 (36.84%), 2-1 (23.68%), 1-2-1 (15.79%), 1-2 (2.63%), 2-2 (13.17%), 2-1-2-1 (5.26%), 1-3-1 (2.63%). The distolingual root of mandibular first molars consisted of type 1-1 (100%). Mesial root of mandibular second molars of type 1-1 (2.63%), 2-1 (50%), 1-2-1 (5.26%), 2-2 (36.85%), 2-1-2-1 (2.63%), 1-2-1-2 (2.63%), distal root type 1-1 (57.89%), 2-1 (15.79%), 1-2-1 (13.16%), 2-2 (10.53%), 2-1-2 (2.63%). This variation of the pulp canal can be influenced by the shape of roots. A flat root usually contains pulp canal configuration type II – VIII Vertucci, similarly to mandibular molar mesial canals. As a summary, there is a variation of pulp canal configuration in mandibular first and second molars on Indonesian Mongoloid race, as seen from the CBCT radiographs.

**Keywords:** mandibular molar, pulp canal configuration, CBCT radiograph, endodontic treatment

## Abstrak

Konfigurasi saluran akar gigi adalah penting diketahui agar perawatan endodonti dapat berhasil. Radiografi cone beam computed tomography (CBCT) dapat membantu dalam menilai konfigurasi saluran akar gigi khususnya pada posisi lingual/palatal dibandingkan dengan radiografi periapikal. Tujuan penelitian ini yaitu untuk mengetahui prevalensi variasi konfigurasi saluran akar gigi molar mandibula pada subpopulasi ras Mongoloid Indonesia dengan menggunakan radiograf CBCT. Penelitian ini adalah penelitian survei deskriptif dengan pendekatan cross-sectional menggunakan 38 radiograf CBCT pasien yang sedang melakukan perawatan gigi di rumah sakit gigi dan mulut di kota Medan dan pemilihan subjek harus memenuhi kriteria penelitian, setelah itu radiograf CBCT diinterpretasi dan dianalisa. Hasil penelitian : Molar satu mandibula akar mesial ditemukan tipe 2-1 (28,94%), 1-2-1 (5,26%), 2-2 (55,26%), 2-1-2-1 (2,64%), 3-2 (5,26%), 3-1 (2,64%), sedangkan akar distalnya tipe 1-1 (36,84%), 2-1 (23,68%), 1-2-1 (15,79%), 1-2 (2,63%), 2-2 (13,17%), 2-1-2-1 (5,26%), 1-3-1 (2,63%). Pada akar distolingual molar satu mandibular adalah tipe 1-1 (100%). Gigi molar dua mandibula akar mesial tipe 1-1 (2,63%), 2-1 (50%), 1-2-1 (5,26%), 2-2 (36,85%), 2-1-2-1 (2,63%), 1-2-1-2 (2,63%), akar distal tipe 1-1 (57,89%), 2-1 (15,79%), 1-2-1 (13,16%), 2-2 (10,53%), 2-1-2 (2,63%). Variasi saluran akar gigi dapat dipengaruhi oleh bentuk akar gigi. Bentuk akar yang flat cenderung dapat dijumpai variasi konfigurasi saluran akar gigi (tipe II-VIII Vertucci) seperti pada akar mesial molar mandibular. Sebagai kesimpulan, terdapat variasi konfigurasi saluran akar gigi molar satu dan molar dua mandibula pada ras Mongoloid di Indonesia yang dijumpai dengan menggunakan radiografi CBCT.

**Kata Kunci:** Molar mandibula, konfigurasi saluran akar gigi, radiografi CBCT, perawatan endodontic.

## INTRODUCTION

The teeth with caries deep into the pulp may avoid an extraction by having endodontic treatment. But before treatment, it is important to have a thorough clinical plan to prevent maltreatment. Knowledge of pulp canal morphology is vital in performing endodontic treatment. In order to learn the condition of pulp canal treatment, we can use periapical radiography with tube shift technique (buccal object rule). However, it is best with CBCT. Periapical radiography depicts two-dimensional condition from three-dimensional object, thus it is not able to show the whole configuration of pulp canal as well as overlapping canal. On the contrary, CBCT can provide three-dimensional picture.<sup>1</sup>

The previous research stated that human permanent pulp canal has varied configurations.<sup>2</sup> Mandibular molars allegedly have more configuration compared to other teeth, as seen through CBCT radiography. This research conducted by Martins et al found the mandibular molar pulp canal configuration on Caucasian population. Mesial root of mandibular first molars consisted of type 1-1 (1.1%), type 2-1 (46.5%), type 2-2 (41.9%), type 2-1-2 (4.1%), type 2-1-2-1 (0.9%), type 3-2 (2.1%), type 2-3-2 (0.2%), type 3-2-1 (3.2%), while distal root consisted of type 1-1 (70.9%), type 2-1 (12.4%), type 1-2-1 (9.6%), type 2-2 (2.3%), type 1-2 (3.2%), type 2-1-2 (0.9%), type 1-2-1-2-1 (0.2%), type 2-1-2-1 (0.5%). Mesial root of mandibular second molars consisted of type 1-1 (8.1%), type 2-1 (63.9%), type 1-2-1 (5.2%), type 2-2 (18.1%), type 1-2 (0.5%), type 2-1-2 (1.6%), type 2-1-2-1 (0.4%), type 3-2 (0.2%), type 3-2-1 (1.4%), type 2-3-2-1 (0.4%), type 3-2-3-2-1 (0.2%), distal root of type 1-1 (93.5%), type 2-1 (0.5%), type 1-2-1 (4.2%), type 2-2 (0.4%), and type 1-2 (1.4%).<sup>3</sup>

Mandibular molar pulp canal configurations were also found in Asian ethnic group. Mesial root of mandibular first molars consisted of type 1-1 (4.5%), type 2-1 (12.3%), type 1-2-1 (3.6%), type 2-2 (76.8%), type 1-2 (2.7%), and distal root of type 1-1 (79.5%), type 2-1 (5.5%), type 1-2-1 (3.2%), type 2-2 (7.7%), type 1-2 (4.1%). The configuration of mesial root of mandibular second molars were of type 1-1 (29.8%), type 2-1 (29.8%), type 1-2-1 (11.5%), type 2-2 (22.1%), type 1-2 (6.9%), and distal root of type 1-1 (98.5%), type 2-1 (0.8%), type 1-2 (0.8%).<sup>4</sup>

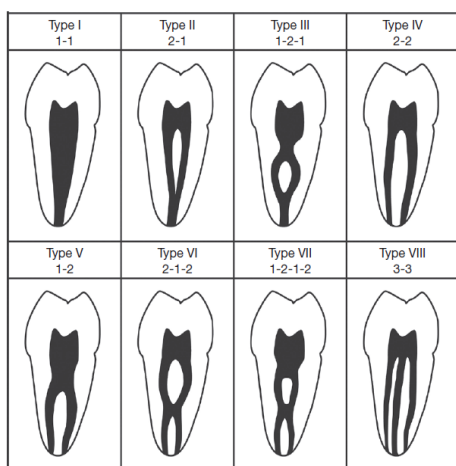
Mandibular molar pulp canal configurations were also found in Malaysian population. The mesial root

of mandibular first molars consisted of type 1-1 (4%), type 2-1 (2.1%), type 2-2 (93.1%), type 1-2-1-2 (2.4%), and distal root of type 1-1 (75.9%), type 2-1 (2.1%), type 2-2 (21.7%), type 2-1-2 (0.3%). Mesial root of mandibular second molars were of type 1-1 (17.7%), type 2-1 (4.2%), type 2-2 (78.1%), and distal root of type 1-1 (96.9%), type 2-2 (3.1%).<sup>5</sup> The majority of Indonesian people are of Mongoloid race. Thus, this research was conducted to find the prevalence of posterior mandibular pulp canal configuration using cone-beam computed tomography (CBCT) radiography.

## MATERIAL AND METHODS

This research was approved by ethics and research commission at Medical Faculty of Universitas Sumatera Utara/RSUP Haji Medan no: 374/TGL/KEPK FK-USU-RSUP HAM/2017. This research is a descriptive survey with the cross-sectional approach, using 38 CBCT radiographs from the patients undergoing dental treatments Universitas Sumatera Utara Hospital (RSGM USU), conducted in April – July 2017 in Medan, Indonesia. Previously, patients took their CBCT picture at Columbia Asia Hospital. Afterwards, pictures were selected based on research criteria. Inclusive criteria include: Mongoloid race, age above 18, clear projection of mandibular molars (except the third molar) and roots with good conditions without apical periodontitis. Exclusive criteria include canal treatment and root fracture. The ignored criteria are teeth with form anomalies such as dilated root and taurodontism.

Research began with sample collection from patient records at RSGM USU. Data were collected and adjusted to the inclusive and exclusive criteria. Afterwards, CBCT pictures were analysed with Planmeca Romexis Viewer 2.9.2.R software. The result showed pulp canals in axial, sagittal and coronal shapes, which were then assessed and analysed to find the frequency and percentage of variation according to Vertucci classification (Figure 1).

Figure 1. Pulp canal variation according to Vertucci.<sup>6,7</sup>

Pulp Canal type, according to Vertucci classification, is divided into 8 types. Type I is a single root canal from pulp to apex (type 1-1). Type II is two canals from the base of pulp chamber merges into one canal towards the apex (type 2-1). Type III is one canal from the base of the pulp chamber, separated into two canals, then merge back into one towards apex (type 1-2-1). Type IV is two canals from the base of the pulp chamber straight to the apex (type 2-2). Type V is one canal from the base of pulp chamber that separates into two canals heading to the apex (1-2). Type VI is two canals from the base of pulp chamber merges into one canal, then separate as it reaches apex (2-1-2). Type VII is one canal from the base of pulp chamber separates into two canals, merge into one, separated, merge back and finally separate their ways into apex (1-2-1-2). Type VIII is three canals from the base of the pulp chamber straight into apex (type 3-3).<sup>6,7</sup>

Data collection will be tabulated and descriptively analysed. This research uses Microsoft Excel for result analysis using the following formula:  $P = F/N \times 100\%$  (P= Percentage, F= Frequency, N = Total Amount).

## RESULTS

The analysis of 38 CBCT radiographs showed that the whole first and second premolars have one root, while mandibular second molars have two roots: mesial and distal. In contrast, there are two and three roots in mandibular first molars. (Table 1).

Table 1. Prevalence of the number of roots in mandibular first and second molars

Teeth	Root F (%)			Total N(%)
	1	2	3	
M1*	-	37 (97.36)	1 (2.64)	38 (100)
M2**	-	38 (100)	-	38 (100)

\*First molars

\*\*Second molars

Pulp canal configuration in this research showed the existence of other canals outside Vertucci type (Table 2). In mandibular first premolars, there were canals type 1-1 (60.52%), 2-1 (10.53%), 1-2-1 (15.79%), 1-2 (10.53%), 2-2 (2.63%), in mandibular second premolars, type 1-1 (65.79%), 2-1 (21.05%), 1-2-1 (13.16%). Mesial canal mandibular first molars consisted of type 2-1 (28.94%), 1-2-1 (5.26%), 2-2 (55.26%), 2-1-2-1 (2.64%), 3-2 (5.26%), 3-1 (2.64%), while in distal canals, type 1-1 (36.84%), 2-1 (23.68%), 1-2-1 (15.79%), 1-2 (2.63%), 2-2 (13.17%), 2-1-2-1 (5.26%), 1-3-1 (2.63%). Mesial canals in mandibular second molars, type 1-1 (2.63%), 2-1 (50%), 1-2-1 (5.26%), 2-2 (36.85%), 2-1-2-1 (2.63%), 1-2-1-2 (2.63%), while the distal canals, type 1-1 (57.89%), 2-1 (15.79%), 1-2-1 (13.16%), 2-2 (10.53%), 2-1-2 (2.63%).

Table 2. Frequency and Percentage of Posterior Mandibular Pulp Canal by Radiography CBCT

Teeth	Pulp Canal Type F (%)												Total N (%)
	Vertucci Classification								Other Type				
	1-1	2-1	1-2-1	2-2	1-2	2-1-2	1-2-1-2	3-3	2-1-2-1	3-1	1-3-1	3-2	
Mesial Root		11/	2/	21/					1/	1/		2/	38/
Mandibular	-	28.	5.26	55.2	-	-	-	-	2.64	2.6	-	5.26	100
First Molar		94		6						4			
Distal Root	14/	9/	6/	5/	1/				2/		1/		38/
Mandibular	36.	23.	15.	13.	2.63	-	-	-	5.26	-	2.63	-	100

First Molar	84	68	79	17									
Disto- Lingual Root Mandibular First Molar (Radix Entomolaris)	1/ 100	-	-	-	-	-	-	-	-	-	-	-	1/10 0
Mesial Root Mandibular Second Molar	1 2.6 3	19/ 50	2/ 5.26	14/ 36.8 5	-	-	1/ 2.63	-	1/ 2.63	-	-	-	38/ 100
Distal Root Mandibular Second Molar	22/ 57. 89	6/ 15. 79	5/ 13.1 6	4/ 10.5 3	-	1/ 2.63	-	-	-	-	-	-	38/ 100

## DISCUSSION

Molar teeth are a part of posterior teeth that usually have two roots, but previous researchers found that mandibular molars might have more than two roots. Ni *et al.* research through CBCT radiography that mandibular first molar in China population found two roots at 74.9% and three roots at 25%. While in Iran population, there were 96.7% two-rooted and 33% three-rooted molars.<sup>9</sup> In contrary with Sudan population, only 3% three-rooted first molars were found.<sup>10</sup>

In this research, only mandibular second molars are 100% two-rooted, while mandibular first molars have 97.36% with the rest 2.64% three-rooted (Table 1). The additional root is often called radix entomolaris (RE). The aetiology of RE remains unknown, but it is often related to the difference in genetic factors during odontogenesis. On the other side, the different result in every population is associated with racial genetic factors that it affects certain genetic expression in producing phenotype forms.<sup>11,12</sup>

Pulp canal is located in the internal section of root. There were several pulp canal configurations found through CBCT radiography in previous researches. Shaaraan and Elrawdy found that in mandibular first molars, 83.94% type 2-2 (type IV Vertucci) was found in the mesial root, and 62.84% type 1-1 (type I Vertucci) in distal root. While in mandibular second molars, most canals found in mesial root were type 2-1 (type II Vertucci) 57.71% and in the distal root, there was type 1-1 (type I Vertucci).<sup>13</sup>

Ni *et al.* research on China population were that there was 76.1% type 2-2 (type IV Vertucci) in mandibular first molars mesial root and 75.6% type 1-1

(type I Vertucci) in the distal root. The canal prevalence in distolingual roots was 100 type 1-1 (type I Vertucci).<sup>8</sup> Pawar *et al.* research in India population through CBCT found that mandibular second molar canal configuration was more varied compared to the distal root. In mesial root, there was 45.17% type 2-2 (type IV Vertucci) and 32.55% type 2-1 (type II Vertucci), while in the distal root, there was 61.14% type 1-1 (type I Vertucci). Meanwhile, in three-rooted mandibular molar, there was 100% type 1-1 (type I Vertucci).<sup>14</sup>

Through CBCT radiography, pulp canal configuration was clearly seen in sagittal, axial and coronal shapes. Table 2 shows that the dominant canal in mandibular first molar mesial root is type 2-2 (type IV Vertucci) at 55.26%, while type 1-1 was found more in distal root at 36.84%. In the mandibular second molar mesial root, there was 50% type 2-1 (type II Vertucci) and 57.89% type 1-1 (type I Vertucci) in distal root. Meanwhile, distolingual root had 100% type 1-1 (type I Vertucci).

This result is similar to Ni *et al.*, Sharaan and Elrawdy and Pawar *et al.*'s research, that canal type 1-1 (type I Vertucci) was found more in distal root, both mandibular first or second molars.<sup>8,13,14</sup> The other similarity is that there are more variations in mesial root compared to distal root. This result is associated with mesial and distal root morphology in mandibular molar. According to Ahmed *et al.*, mandibular molar mesial root has flat shape, while distal root can be conical and flat. The flat root is wider than conical ones.<sup>10</sup>

Pulp canal variation in this research can be found in the distal root, most probably caused by the flat root. According to Demiriz *et al.*, CBCT radiography shows there are more flat roots found in molars com-

pared to conical root. In flat roots, there are various canals from type I to VIII Vertucci with ranging percentages. Whereas conical roots only show type I to IV Vertucci.<sup>15</sup>

The only shortcoming from this research is the smaller amount of radiograph samples, causing less variation compared with previous research.

The most effective way to depict the pulp canal is through periapical radiography with tube shift tech-

nique. This research shows mandibular first and second molar pulp canal configuration in Indonesia Mongoloid subpopulation. In order to perform a successful endodontic treatment, it is important for a dentist to diagnose the correct pulp canal beforehand. Thus, modern analysis through CBCT is the best alternative.

## REFERENCES

1. Estrela C, Pecora JD, Estrela CRA, Guedes OA, Silva BSF, Soares CJ, Sousa-Neto MD. Common operative procedural errors and clinical factors associated with root canal treatment. *Braz Dent J* 2017; 28(2): 179-90.
2. Amardeep NS, Raghu S, Natanasabapathy V. Root canal morphology of permanent maxillary and mandibular canines in Indian population using cone beam computed tomography. *Anat Res. Int.* 2014; 2014: 1-8.
3. Martins JNR, Marques D, Mata A, Carames J. Root and root canal morphology of the permanent dentition in a Caucasian population: cone beam computed tomography study. *Int. J. Dent. J.* 2017; 50: 1013-026.
4. Martins JNR, Gu Y, Marques D, Francisco H, Carames J. Differences on the root and root canal morphologies between Asia and White ethnic groups analysed by cone beam computed tomography. *J Endod* 2018; 1-9.
5. Pan JYY, Parolia A, Chuah SR, Bhatia S, Mutalik S, Pau A. Root canal morphology of permanent teeth in a Malaysian subpopulation using cone beam computed tomography. *BMC Oral Health* 2019; 19: 1-15.
6. Torres A, Jacobs R, Lambrechts P, Brizuela C, Cabrera C, Concha G, Pedemonte ME. Characterization of mandibular molar root and canal morphology using cone beam computed tomography and its variability in Belgian and Chilean population samples. *Imaging Sci Dent* 2015; 45: 95-101.
7. Bansal R, Hegde S, Astekar MS. Classification of root canal configurations: a review and a new proposal of nomenclature system for root canal configuration. *JCDR* 2018; 12(5): 1-5.
8. Ni N, Cao S, Han L, Zhang L, Ye J, Zhang C. Cone-beam computed tomography analysis of root canal morphology in mandibular first molars in a Chinese population: a clinical study. *Evid-Based Endod.* 2018; 3: 1-6.
9. Akhlaghi NM, Khalilak Z, Vatanpour M, Mohammadi S, Pirmoradi S, Fazlyab M, Safavi K. Root canal anatomy and morphology of mandibular first molars in a selected Iranian population: an in vitro study. *IEJ* 2017; 12(1): 87-91.
10. Ahmed HA, Abu-bakr NH, Yahia NA, Ibrahim YE. Root and canal morphology of permanent mandibular molars in a Sudanese population. *IEJ* 2007; 40: 766-71.
11. Van der Vyver PJ, Vorster M. Radix entomolaris: literature review and case report. *SADJ* 2017; 72(3): 113-17.
12. Kuzekanani M, Walsh LJ, Haghani J, Kermani AZ. Radix entomolaris in the mandibular molar teeth of an Iranian population. *Int J Dent* 2017; 1-4.
13. Sharaan ME, Elrawdy AM. An evaluation of mandibular molars root canal morphology using cone beam computed tomography in an Egyptian subpopulation. *Tanta Dent J* 2017; 14(4): 220-24.
14. Pawar AM, Pawar M, Kfir A, Singh S, Salve P, Thakur B, Neelakantan P. Root canal morphology and variations in mandibular second molar teeth of an Indian population: an in vivo cone beam computed tomography analysis. *Clin Oral Invest* 2017; 21(9): 2801-809.
15. Demiriz I, Bodrumlu EH, Icen M. Evaluation of root canal morphology of human primary mandibular second molars by using cone beam computed tomography. *Niger J Clin Pract* 2018; 21(4): 462-67.